DERMAGOLD™

MultiWave™ System for Wounds and Tendonopathies

CASE REPORTS

TRT
Tissue Regeneration & Lithotripsy

Our Company

TRT is the world leader in the research and development of pressure pulse *(i.e. acoustical wave)* technology for treatment of chronic and non-chronic tissue trauma including non-healing wounds, skin lesions, ulcers, and burns. TRT administers and sponsors a multitude of human and animal wound care trials internationally using its soft focused pressure-pulse technology *(MultiWave™ technology)*.

TRT is currently conducting FDA studies in the United States on the treatment of traumatic extemity wounds and plantar fasciitis using its DermaGold™ soft focused MuliWave™ device.

Our Soft Focused MultiWave™ Technology

TRT's MultiWave™ technology differs from traditional ESWT *(extracorporeal shockwave therapy)* in that MultiWave™ technology uses soft focused acoustical wave pattern, including planar or nearly planar and divergent acoustical waves, to initiate healing.

Traditional ESWT historically is endorsed by the shockwave industry as technology propagating focused *(i.e. coming to a point)* acoustical wave patterns that initially induce trauma to tissue in the focal area, followed by a neovascular response.

Contrary to traditional ESWT, TRT's soft focused MultiWave™ technology does not require patient anesthesia.

Our Case Reports

Hundreds of patients with traumatic wound conditions have been treated internationally with TRT's DermaGold™ soft focused MultiWave™ device, including patients who were previously scheduled for amputation and patients with necrotic skin conditions.

The following case studies were conducted solely using TRT's DermaGold™ soft focused MultiWave™ device unless otherwise indicated.

Figure 1

Figure 2

Figure 3

Figure 4

- Figure 1 shows the forearm of a 94- year- old female patient after a para-venously applied infusion and two septical revisions. An abating infection with penicillin-resistant staphylococcus aureus was diagnosed (positive smear test). Because of a chronic COPD the patient is being treated with cortisone. The patient also suffers from chronic lymphatic leukemia. The first treatment was applied on 10/13/2004 as an outpatient procedure without anesthetics.
- Figure 2 shows the same patient 2 weeks after the first treatment. A pre-existing therapy with antibiotics was discontinued and the second treatment (again without anesthetics) was applied.
- Figure 3 shows the healing status 6 weeks after starting the therapy. In total, four treatments were given.
- Figure 4 shows the patient two years after treatment.

CASE STUDY #1

Forearm of a 94-Year-Old Female

TRT
Tissue Regeneration & Lithotripsy

© Copyright Tissue Regeneration Technologies (TRT). All Rights Reserved.

CASE STUDY #2

Barefoot of a 47-Year-Old Male

- Figure 1 shows the forearm of a 94- year- old female patient after a para-venously applied infusion and two septical revisions. An abating infection with penicillin-resistant staphylococcus aureus was diagnosed (positive smear test). Because of a chronic COPD the patient is being treated with cortisone. The patient also suffers from chronic lymphatic leukemia. The first treatment was applied on 10/13/2004 as an outpatient procedure without anesthetics.

- Figure 2 shows the same patient 2 weeks after the first treatment. A pre-existing therapy with antibiotics was discontinued and the second treatment (again without anesthetics) was applied.

- Figure 3 shows the healing status 6 weeks after starting the therapy. In total, four treatments were given.

- Figure 4 shows the patient two years after treatment.

Figure 1

Figure 2

Figure 3

Figure 4

CASE STUDY #3

Infected Ulcer of an 80-Year-Old Female

- Figure 1 shows an 80-year old female patient who developed a huge infected decubitus ulcer from a lengthy stay in a hospital bed after a knee operation. She was treated with high dose antibiotics. Surgeons recommended a colostomy and several operations to clean the wound. Her family, fearing she would pass away from surgical procedures, withdrew the patient from the hospital and took her to Dr. Richard Thiele for treatment with the DermaGold™ soft focused Multiwave™ device. Antibiotics were discontinued, and the patient was mobilized. She received her first treatment on July 5, 2006. The size of the wound prior to the first DermaGold treatment was 18 cm long x 15 cm wide x 8 cm deep.

- Figure 2 shows the same patient 6 weeks later (August 17, 2006) prior to the 6th DermaGold treatment. The size of the wound had decreased to 10 cm long x 8 cm wide x 6 cm deep (77% decrease).

- Figure 3 shows the same patient on September 20, 2006 prior to the 11th weekly DermaGold treatment. The size of the wound had decreased to 8 cm long x 6 cm wide x 5 cm deep (88% decrease).

- Figure 4 shows the patient on November 22, 2006 prior to the 20th DermaGold treatment. The size of the wound had decreased to 3 cm long x 1.5 cm wide x 2 cm deep (99.6% decrease).

- Continuous weekly treatments are planned.

Figure 1

Figure 2

Figure 3

Figure 4

CASE STUDY #4

Left Clavicle of a 43-Year-Old Male

Figure 1

Figure 2

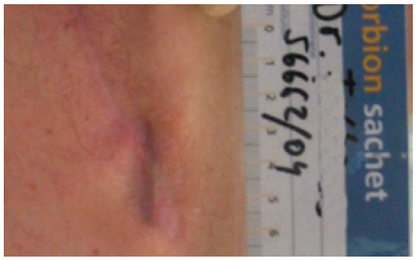

Figure 3

- Figure 1 shows the post-operative situs of a 43-year-old male patient 10 days after plating his left clavicle due to a fracture. This photo was taken prior to the first treatment.
- Figure 2 shows the same patient 12 days later, prior to the second treatment. The wound was completely epithelialized 3 weeks after the first treatment.
- Figure 3 shows the same patient 4 months later, before removal of the plate.

CASE STUDY #5

Compression Ulcer on the Left Foot of a 50-Year-Old Male

Figure 1

Figure 2

- Figure 1 shows the left foot of a 50-year-old paraplegic male patient with a compression ulcer, prior to first treatment.
- Figure 2 shows the same patient two weeks after treatment.

CASE STUDY #6

Right Hand of a 38-Year-Old Male *(Motor Saw Accident)*

Figure 1

Figure 1

- Figure 1 shows the right hand of a 38-year-old male patient after multiple surgeries after a complex trauma with a motor saw. The free flap transplanted to his forearm had insufficient blood supply in its distal part and became necrotic. The picture shows the wound before the first treatment.

Figure 2 shows the same patient 6 weeks later, after
7 treatments, completely epithelialized.

WOUNDS:

Before and After

Figure 1

Figure 2

Figure 3

Figure 4

TRT

Tissue Regeneration Technologies

The biological effect of shock waves can be specifically utilized to generate new tissue formation and successfully treat skin lesions.

POWERED BY

MTS

Shockwave Technology & Lithotripsy

110 Arnold Mill Park | Suite 400 | Woodstock, GA 30188
Phone: 770-966-1315 | Toll Free: 877-966-1315 | Fax: 770-592-8910 | www.trtllc.com